JURNAL LOCUS: Penelitian & Pengabdian
Volume 5 No. 9 September 2026
E-ISSN 2829-7334| P-ISSN 2829-5439
Hompage: https://locus.rivierapublishing.id/index.php/jl

Protective Stabilization for Dental Management in a Child with Developmental Language Disorder: A Case Report

Marta Ulina Naibaho, Ratna Indriyanti*
Universitas Padjadjaran, Indonesia
Email: marta23001@mail.unpad.ac.id, ratna.indriyanti@fkg.unpad.ac.id*

Keywords:
Special Health Care Needs; Developmental Language Disorder; Protective Stabilization; Papoose Board; Case Report.

Abstract

Children with Special Health Care Needs (SHCN) often present behavioral and developmental challenges, including Autism Spectrum Disorder (ASD), a neurodevelopmental condition characterized by deficits in social communication and restricted, repetitive patterns of behavior. ASD may also involve persistent difficulties in understanding and using spoken language, which can complicate oral health care. General Anesthesia (GA) is commonly used for full-mouth rehabilitation in uncooperative children with SHCN; however, parental concerns regarding safety, cost, or cultural beliefs may limit its acceptability. Protective Stabilization (PS), including the use of a papoose board, is a non-pharmacological alternative recommended by the American Academy of Pediatric Dentistry (AAPD). A 7-year-old boy with ASD and associated speech and language delay presented with recurrent discomfort during eating, frequent food impaction, and difficulty expressing pain. The family, who resided in Saudi Arabia, was visiting Indonesia and sought care at the Pediatric Dentistry Clinic, Universitas Padjadjaran Dental Hospital, Bandung. Although GA is commonly used for dental rehabilitation in Saudi Arabia, the parents declined this approach due to cultural and familial concerns regarding their child "falling asleep" during GA and provided consent for PS. Clinical findings included generalized calculus and reversible pulpitis involving multiple primary molars. No carious lesions with pulpal involvement were detected. This case illustrates the challenges of providing dental treatment for children with ASD, in whom communication barriers may hinder cooperation. PS enabled safe and effective dental care, resolving food impaction and improving oral comfort. The literature regarding PS use in children with ASD remains limited, highlighting the need for further clinical reports. PS provided a safe and effective alternative to GA in this child with Developmental Language Disorder (DLD), emphasizing the importance of individualized, family-centered, non-pharmacological approaches.

INTRODUCTION

Children with Special Health Care Needs (SHCN) often experience developmental and behavioral conditions that make the provision of oral health care more challenging. Among these conditions, Autism Spectrum Disorder (ASD) is a prevalent neurodevelopmental disorder characterized by persistent impairments in social communication and social interaction, accompanied by restricted and repetitive behaviors, interests, or activities. In addition, many children with ASD exhibit delays in both receptive and expressive language development, which may limit their ability to cooperate during dental procedures and create additional challenges in behavioral management during treatment (AlBhaisi et al., 2022; Delli et al., 2013).

The prevalence of Autism Spectrum Disorder (ASD) has increased markedly over the past few decades. Data from the Autism and Developmental Disabilities Monitoring (ADDM) Network indicate that approximately one in every 36 children aged eight years in the United States was diagnosed with ASD in 2020, while global estimates suggest a prevalence of approximately one in 100 children (Maenner et al., 2023; Zeidan et al., 2022). The increasing number of individuals affected by ASD underscores the importance of equipping dental professionals with effective management strategies to provide care that is safe, acceptable, and responsive to the unique needs of this population (AlBhaisi et al., 2022).

Children with ASD experience a disproportionately high burden of oral health problems. Previous studies have reported that the prevalence of dental caries in this population ranges from 60% to 67%, accompanied by higher rates of periodontal disease and an increased likelihood of requiring dental treatment under general anesthesia (Narula et al., 2024). Multiple factors contribute to these adverse oral health outcomes, including communication difficulties, behavioral challenges, sensory processing abnormalities, limited ability to perform routine oral hygiene practices independently, and reduced cooperation during dental visits. Collectively, these barriers often result in delayed access to care and a higher prevalence of unmet dental treatment needs among children with ASD (Al-Beltagi et al., 2025; Bernath & Kanji, 2021; Erwin et al., 2022; Jones et al., 2024; Kangutkar et al., 2024).

In pediatric dental practice, most children can be successfully treated using basic behavior guidance techniques, which serve as the cornerstone of patient management. However, children with developmental, cognitive, or communication impairments may exhibit behaviors such as severe anxiety, impulsivity, aggression, or self-injurious behaviors that compromise the safety of both the patient and the dental team. In these circumstances, advanced behavior guidance strategies may be required to facilitate communication, improve cooperation, and enable the provision of safe and effective dental care (American Academy of Pediatric Dentistry [AAPD], 2023).

General anesthesia (GA) is widely utilized for comprehensive dental treatment in children with Special Health Care Needs (SHCN), particularly those who are unable to cooperate adequately during dental procedures. By providing a controlled environment and minimizing behavioral barriers, GA allows extensive treatment to be completed efficiently in a single visit. Previous studies have reported considerable reliance on GA among children with Autism Spectrum Disorder (ASD) requiring comprehensive oral rehabilitation (Narula et al., 2024). Despite its clinical advantages, parental acceptance of GA may be limited due to concerns regarding potential risks, financial burden, cultural considerations, or restricted access to specialized services. Consequently, alternative non-pharmacological approaches to behavior management remain important in pediatric dental care (Alkahtani, 2025; Chen et al., 2024; Kaur et al., 2025; Kong et al., 2024; Trusculescu et al., 2025).

Protective stabilization (PS), including the use of devices such as a papoose board, represents one of the advanced behavior guidance techniques recommended by the American Academy of Pediatric Dentistry (AAPD) when conventional behavior guidance methods have proven ineffective and pharmacological interventions are either declined or considered inappropriate (AAPD, 2023; Casamassimo et al., 2022). PS involves the judicious and temporary restriction of patient movement to minimize the risk of injury and facilitate the safe delivery of dental treatment (Casamassimo et al., 2022). Although this technique is occasionally employed in the

management of children with ASD, evidence describing its application and clinical outcomes in this population remains relatively scarce (Ilha et al., 2021)†. Therefore, this case report describes the use of protective stabilization as an alternative to general anesthesia in the dental management of a child with ASD and highlights the importance of individualized, family-centered decision-making in addressing the behavioral and clinical needs of children with special health care needs.

Anamnesis

A 7-year-old boy with ASD and associated speech and language delay presented to the Pediatric Dentistry Clinic, Universitas Padjadjaran Dental Hospital (RSGM UNPAD), Bandung, accompanied by his family. The chief complaint was recurrent discomfort during eating, with food frequently becoming impacted between the teeth, and difficulty expressing the resulting pain. The family ordinarily resides in Saudi Arabia and was visiting relatives and on a short holiday in Indonesia at the time of presentation.

The standard treatment approach offered in Saudi Arabia had been comprehensive dental rehabilitation under general anesthesia (GA). However, the parents declined GA owing to cultural and familial concerns about their child "falling asleep," and consented instead to a non-pharmacological approach using protective stabilization. The patient was diagnosed with ASD by a developmental pediatrician and has received sensory-integration therapy, occupational therapy, and speech therapy. A psychological evaluation documented primitive reflexes that were not fully integrated, affecting attention and concentration, together with difficulty maintaining sustained eye contact.

The patient was born to non-consanguineous parents. The mother was 37 years old at the time of pregnancy and had a medical history of asthma and mildly elevated blood pressure, consistent with white-coat hypertension, for which antihypertensive medication was prescribed. The father was 39 years old and had a history of hypertension. There was no history of maternal smoking during pregnancy.

The pregnancy resulted in the delivery of a full-term infant at 38–39 weeks of gestation under the supervision of a hospital physician. Delivery occurred spontaneously and was complicated by a double-loop nuchal cord. Despite this finding, the infant cried immediately after birth and had a birth weight of 3,880 g.

During the postnatal period, the patient was exclusively breastfed for the first six months of life without feeding-related complications. In the first week after birth, neonatal jaundice developed and was managed successfully with phototherapy administered from the second to the fourth day of life. Growth and weight gain during infancy were reported to be appropriate for age, and no other significant medical complications were noted during the first year of life.

Developmental assessment revealed generally age-appropriate attainment of gross motor milestones, including crawling at 9 months, standing at 10 months, and independent sitting at 6 months. However, a mild delay in independent walking was observed, with ambulation achieved at 19 months of age. The most prominent developmental concern was a marked delay in language acquisition, as the patient did not produce meaningful first words until approximately 6 years of age. Reduced eye contact was also noted during early infancy, becoming apparent at around 3 months of age.

The family pedigree was consistent with a multifactorial inheritance pattern, with the proband (the patient) affected by speech delay and autism (Figure 1).

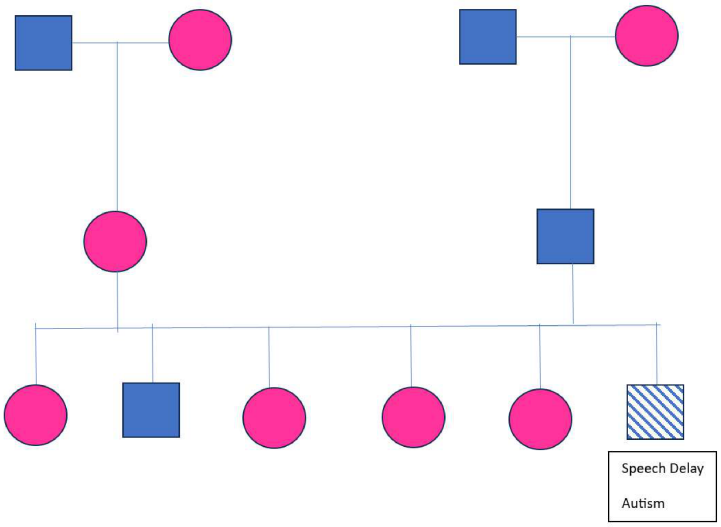

Figure 1. Patient pedigree, consistent with a multifactorial pattern; the proband is affected by speech delay and autism spectrum disorder.

Patient Examination

1. Physical Profile

Physical examination demonstrated normal muscle tone, gait, body posture, neck posture, and craniofacial growth, including normal head size and shape. The morphology of the fingers, toes, hair, eyes, and ears was unremarkable. A relatively flat facial profile was observed. The only notable abnormality was impaired speech development, consistent with the patient's previously documented speech and language delay.

2. Dental History

According to parental reports, the patient's first primary tooth erupted at 10 months of age, which was considered within the normal developmental range. The child consumed solid foods and did not have a history of pacifier use; however, a tendency to retain food in the mouth for prolonged periods was noted. Oral hygiene was performed with assistance from both parents, and toothbrushing was carried out twice daily, after waking in the morning and before the evening bath. The patient had a history of dental pain, previous dental visits, and prior exposure to topical fluoride applications.

3. Extra-oral and Intra-oral Examination

Extra-oral examination revealed no signs or symptoms of temporomandibular joint dysfunction, with no clicking or crepitus detected during mandibular movement. Lip tone was within normal limits, facial symmetry was preserved, and no cervical lymphadenopathy, tenderness, or palpable masses were identified. Intra-oral examination demonstrated a mixed dentition with an age-appropriate number of teeth. The labial frenulum, palate, and occlusion appeared normal, and bilateral tonsils were graded as T2, with no other clinically significant abnormalities observed.



Figure 2. Frontal facial photograph at initial presentation (eyes masked for anonymity).



Figure 3. Body-posture assessment (lateral, frontal, and lateral views); posture within normal limits.

Oral hygiene was assessed using the Silness and Löe plaque index (teeth 16, 12, 24, 36, 32, 44), yielding a score of 0.67, categorized as good. Clinical findings included generalized calculus deposits and reversible pulpitis affecting multiple primary molars. Physiological root resorption of a maxillary second primary incisor was noted, with extraction indicated. No carious lesions with pulpal involvement were detected. The caries risk assessment was categorized as high. The intra-oral clinical photographs are shown in Figure 4.

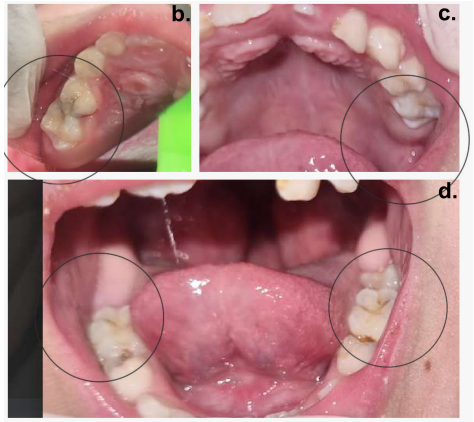

Figure 4. Intra-oral examination: reversible pulpitis with interproximal caries between teeth 55–54 (b), 65–64 (c), and 75–74 and 85–84 (d).

4. Odontogram

Interproximal caries were identified between teeth 55 and 54, 65 and 64, 75 and 74, and 85 and 84. The odontogram is shown in Figure 5.

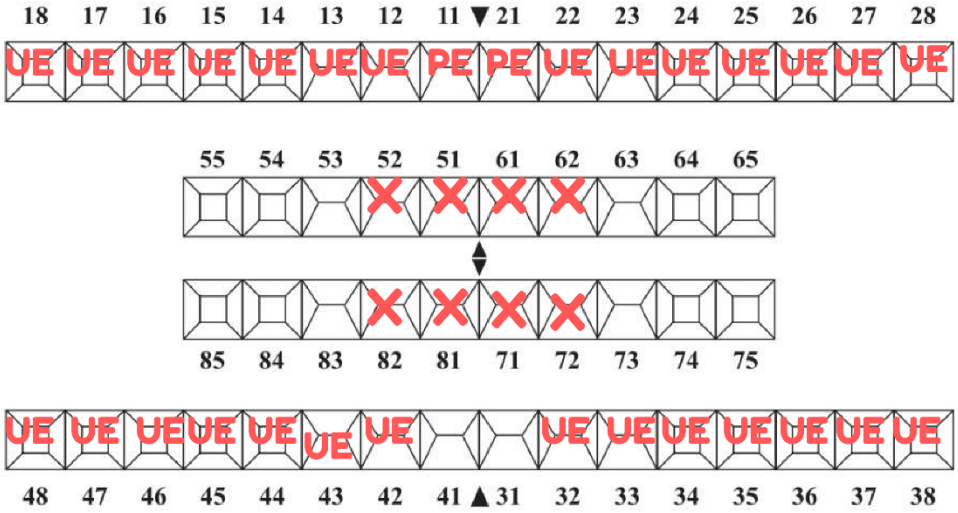

Figure 5. Patient odontogram. UE = unerupted; PE = partially erupted; X = affected primary molars (interproximal caries / reversible pulpitis).

Treatment Plan

A comprehensive, phased treatment plan was formulated to address the patient's active oral disease while accommodating his behavioral and communication profile. Because the parents declined general anesthesia and basic behavior guidance techniques alone were insufficient to permit safe treatment, protective stabilization (PS) with a papoose board was selected as the advanced behavior guidance technique to support each operative procedure. Written informed consent was obtained from the parents prior to treatment, with explicit acknowledgment that consent could be withdrawn at any time before or during the procedure without compromising the quality of care.

Table 1 The planned interventions, sequenced across four visits, are presented in Table 1.

Phase / Visit	Planned procedure	Teeth / Area
Phase I – Preventive (Visit 1)	Manual scaling and oral prophylaxis	Full mouth, including lower anterior region
Phase II – Restorative (Visit 2)	Glass ionomer cement (GIC) restoration	55, 54, 74, 75
Phase II – Restorative (Visit 3)	GIC restoration and topical fluoride application	65, 64, 85, 84; all surfaces
Phase III – Maintenance (Visit 4)	One-week follow-up control; oral-hygiene reinforcement	Full mouth

Instruments and materials prepared for treatment included a size-appropriate papoose board (full-body passive stabilization device), a mouth prop / bite block to assist in maintaining mouth opening, basic dental examination instruments, manual scaling instruments, glass ionomer cement restorative material, and topical fluoride. A protective drape and continuous clinical monitoring of the patient were maintained throughout each procedure.

Treatment Goals

The treatment goals were defined as follows:

1. To eliminate the source of the chief complaint by resolving the interproximal caries and food impaction responsible for recurrent discomfort during eating;

2. To arrest active disease and restore function through removal of calculus, restoration of the affected primary molars, and reduction of caries risk;
3. To deliver care safely for both the patient and the dental team by means of controlled, time-limited immobilization, in accordance with the indications and safeguards recommended by the AAPD;
4. To respect the family's preferences by providing a non-pharmacological alternative to general anesthesia within an individualized, family-centered framework; and
5. To establish a preventive maintenance pathway, including caregiver education and routine dental review appropriate to the mixed-dentition stage.

Case Management

Treatment was carried out over four visits between July and August 2025. At each operative visit, the patient was positioned in the papoose board in the presence of, and with the consent of, his parents; secure immobilization was confirmed before commencing, and each procedure was completed within a limited time frame under continuous monitoring (Figure 6).

Table 2 The chronological progress of treatment is summarized in Table 2.

Visit (date)	Procedure performed	Outcome
Visit 1 (15 July 2025)	Manual scaling and polishing of generalized calculus, including the lower anterior region	Completed under PS; well tolerated
Visit 2 (5 August 2025)	GIC restoration of teeth 55, 54, 74, and 75 (right maxillary and mandibular regions), one area per day	Completed under PS; no complications
Visit 3 (13 August 2025)	GIC restoration of teeth 65, 64, 85, and 84 (left maxillary and mandibular regions) followed by topical fluoride application to all surfaces	Completed under PS; no complications
Visit 4 (24 August 2025)	One-week post-treatment control and oral-hygiene reinforcement	Treatment safe and complete; no adverse events



Figure 6. Step-by-step illustration of protective stabilization (PS) with a papoose board to achieve safe child immobilization during dental treatment.

Caries were removed and each affected primary molar was restored with glass ionomer cement, after which topical fluoride was applied to all tooth surfaces (Figure 7). The patient tolerated PS at every visit, and no airway, soft-tissue, or other complications were encountered.

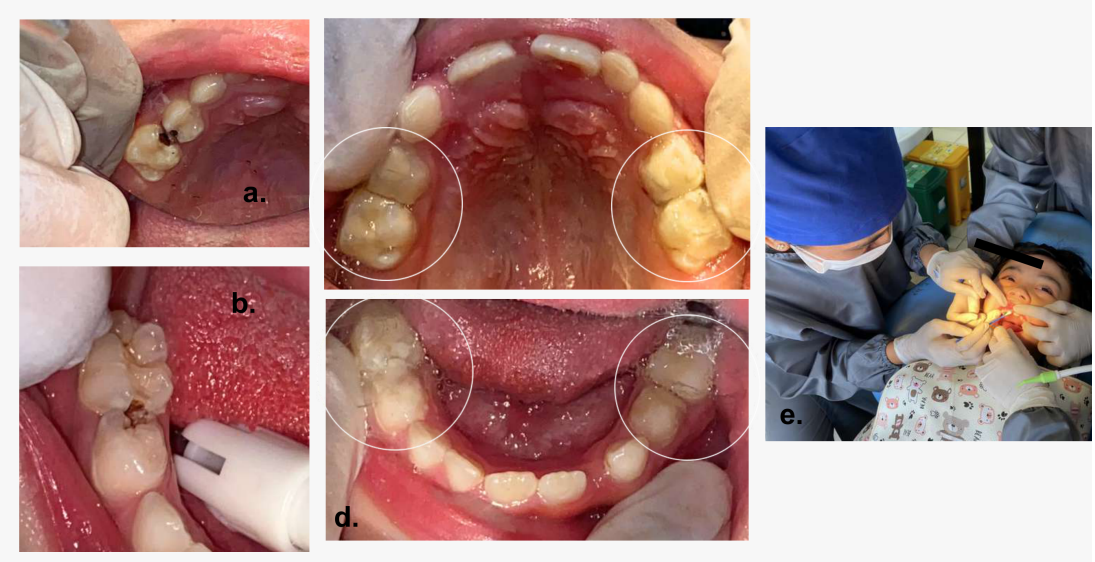

Figure 7. Caries removal in each area per day (a, b); all teeth restored with GIC in the upper and lower arches (c, d); topical fluoride application to all tooth surfaces (e).

Treatment Result

At the one-week control (Visit 4), the rehabilitation was found to have proceeded safely and to completion: the food impaction had been resolved, the patient was visibly more comfortable, and no complications were observed (Figure 8). All planned restorations were intact, and oral hygiene was maintained at a good level.



Figure 8. Dental condition one week after mouth rehabilitation; food impaction resolved, restorations intact, no complications.

At longer-term follow-up (February 2026), the favorable outcome was sustained: the patient and family reported no complaints, with no further food trapping, discomfort, or pain (Figure 9). The subsequent maintenance plan comprised education for parents and caregivers,

periodic monitoring of oral hygiene, routine dental visits, and—given the mixed-dentition stage—prompt dental review should any tooth become mobile.

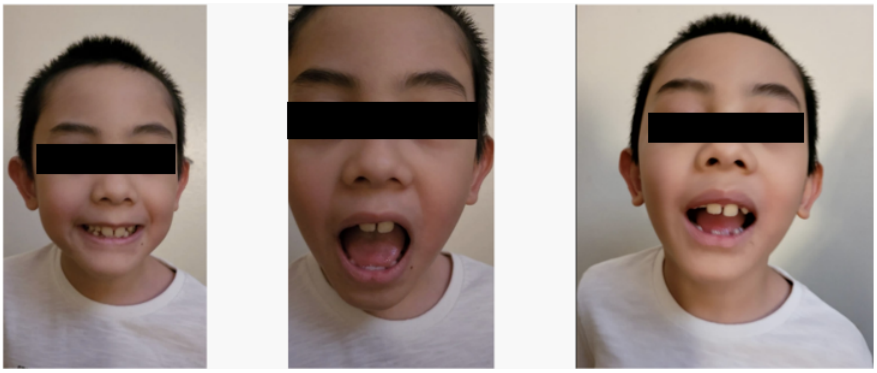

Figure 9. Follow-up facial profile (February 2026); the patient reported no complaints

RESULT AND DISCUSSION

Autism Spectrum Disorder (ASD) presents distinct challenges in pediatric dental practice, where successful treatment depends heavily on effective communication. Children with ASD frequently struggle with both receptive and expressive language and may have heightened behavioral and sensory sensitivities, leaving them less able to follow instructions or signal discomfort (Cermak et al., 2015; Delli et al., 2013). In the present case, these difficulties translated directly into limited cooperation during treatment, complicating the delivery of safe and effective care.

Such limited cooperation is easily mistaken for deliberate non-compliance. In reality, it usually reflects an impaired capacity to process or convey information rather than willful refusal—a distinction that carries real clinical weight, since it shapes the choice of behavior management strategy (Delli et al., 2013). Here, the patient's difficulty in expressing pain and grasping instructions was central to the management challenge, underscoring the need for an approach individualized to his developmental and communication profile.

The oral disease burden among children with ASD is well established, with consistently high prevalences of caries and periodontal disease and substantial unmet treatment needs (Narula et al., 2024). This patient's generalized calculus, reversible pulpitis of multiple primary molars, and food impaction causing recurrent discomfort illustrate how delayed access to care permits disease to advance, reinforcing the value of timely and structured dental intervention in this population.

General anesthesia (GA) is widely considered the standard for managing uncooperative pediatric patients—particularly those with special health care needs requiring comprehensive rehabilitation—and is required in a considerable proportion of children with ASD (Narula et al., 2024). By enabling complete treatment within a controlled setting, GA minimizes both psychological stress and patient movement. In this instance, however, the parents declined GA on cultural and familial grounds, exposing a familiar real-world constraint and prompting the search for an alternative that reconciles clinical effectiveness, patient safety, and family preference.

Protective Stabilization (PS) is one such alternative endorsed by the AAPD for situations in which conventional behavior guidance proves inadequate and pharmacological management is not feasible (AAPD, 2023; Casamassimo et al., 2022). Although recognized among the

advanced behavior guidance techniques applicable to children with ASD, PS is generally reserved for selected cases (Ilha et al., 2021). For this patient, a papoose board allowed controlled immobilization that protected both child and operator throughout treatment. Critically, PS was applied with parental consent and for a limited duration, in keeping with ethical and clinical guidelines (Casamassimo et al., 2022; Mokhtar et al., 2019). The favorable result—treatment completed, food impaction resolved, and comfort restored—confirms that PS can serve as an effective non-pharmacological option in appropriately chosen situations.

Its clinical utility notwithstanding, PS continues to raise ethical questions, especially around patient autonomy and the potential for psychological distress (Ilha et al., 2021). Its use must therefore be deliberately justified, individualized, and monitored throughout. In this case, the benefit of completing essential dental care and halting further deterioration clearly outweighed the potential risks, particularly in the absence of any viable alternative. Where circumstances allow, complementary measures such as desensitization, visual supports, and sensory-adapted dental environments may, over time, lessen the need for advanced techniques (AlBhaisi et al., 2022; Cermak et al., 2015).

Evidence specific to the use of PS in children with ASD remains scarce. Most available studies address children with special health care needs broadly, or mention PS only as a single element within larger behavioral-management series, with little procedural detail (Ilha et al., 2021). This gap underscores the contribution of focused case reports such as the present one and points to a clear need for further research to define clearer guidelines and to assess the long-term outcomes of PS in children with ASD.

CONCLUSION

Protective Stabilization (PS) can serve as a safe and effective alternative to general anesthesia (GA) in the dental management of children with Autism Spectrum Disorder (ASD), particularly when pharmacological approaches are not acceptable to the family. The successful outcome in this case demonstrates the importance of an individualized, patient- and family-centered approach that considers communication abilities, behavioral characteristics, and parental preferences. This report further emphasizes the need for careful clinical and ethical consideration in the use of PS, as well as the value of case reports in contributing to the scientific evidence regarding the dental management of children with ASD.

REFERENCES

Al-Beltagi, M., Al Zahrani, A. A., Mani, B. S., Hantash, E. M., Saeed, N. K., Bediwy, A. S., & Elbeltagi, R. (2025). Challenges and solutions in managing dental problems in children with autism. *World Journal of Clinical Pediatrics, 14*(3), 106778.

AlBhaisi, I. N., Kumar, M. S. T. S., Engapuram, A., Shafiei, Z., Zakaria, A. S. I., Mohd-Said, S., & McGrath, C. (2022). Effectiveness of psychological techniques in dental management for children with autism spectrum disorder: A systematic literature review. *BMC Oral Health, 22*(1), 162. https://doi.org/10.1186/s12903-022-02200-7

Alkahtani, Z. M. (2025). Effectiveness of non-pharmacological interventions in reducing dental anxiety among children with special needs: A scoping review with conceptual map. *Children, 12*(2), 165.

American Academy of Pediatric Dentistry. (2023). Behavior guidance for the pediatric dental patient. In *The reference manual of pediatric dentistry*. American Academy of Pediatric Dentistry.

Bernath, B., & Kanji, Z. (2021). Exploring barriers to oral health care experienced by individuals living with autism spectrum disorder. *Canadian Journal of Dental Hygiene, 55*(3), 160.

Casamassimo, P. S., Meyer, B., & Townsend, J. A. (2022). Pain, psyche and protective stabilization. *Journal of the California Dental Association, 50*(8), 465–471. https://doi.org/10.1080/19424396.2022.12224327

Cermak, S. A., Stein Duker, L. I., Williams, M. E., Dawson, M. E., Lane, C. J., & Polido, J. C. (2015). Sensory adapted dental environments to enhance oral care for children with autism spectrum disorders: A randomized controlled pilot study. *Journal of Autism and Developmental Disorders, 45*(9), 2876–2888. https://doi.org/10.1007/s10803-015-2450-5

Chen, J., Deng, K., Yu, D., Fan, C., Liu, L., Gu, H., Huang, F., & Huo, Y. (2024). Recent developments in the non-pharmacological management of children's behavior based on distraction techniques: A concise review. *Healthcare, 12*(19), 1940.

Delli, K., Reichart, P. A., Bornstein, M. M., & Livas, C. (2013). Management of children with autism spectrum disorder in the dental setting: Concerns, behavioural approaches and recommendations. *Medicina Oral, Patología Oral y Cirugía Bucal, 18*(6), e862–e868. https://doi.org/10.4317/medoral.19084

Erwin, J., Paisi, M., Neill, S., Burns, L., Vassallo, I., Nelder, A., Facenfield, J., Devalia, U., Vassallo, T., & Witton, R. (2022). Factors influencing oral health behaviours, access and delivery of dental care for autistic children and adolescents: A mixed-methods systematic review. *Health Expectations, 25*(4), 1269–1318.

Ilha, M. C., Feldens, C. A., Razera, J., Vivian, A. G., de Rosa Barros Coelho, E. M., & Kramer, P. F. (2021). Protective stabilization in pediatric dentistry: A qualitative study on the perceptions of mothers, psychologists, and pediatric dentists. *International Journal of Paediatric Dentistry, 31*(5), 647–656. https://doi.org/10.1111/ipd.12751

Jones, J., Roberts, E., Cockrell, D., Higgins, D., & Sharma, D. (2024). Barriers to oral health care for autistic individuals—A scoping review. *Healthcare, 12*(1), 103.

Kangutkar, T., Fernando, N., Walsh, O., Lim, M., Milner, K., Thorpe, J., & Silva, M. (2024). Factors influencing the optimal utilisation of dental services by children with developmental concerns, autism spectrum disorder and/or intellectual disability: A qualitative study of caregivers' perspectives. *Autism Spectrum Disorder and/or Intellectual Disability: A Qualitative Study of Caregivers' Perspectives (July 15, 2024)*.

Kaur, K., Saini, R. S., Binduhayyim, R. I. H., Mosaddad, S. A., & Heboyan, A. (2025). Analyzing nonpharmacological behavior management in children with dental anxiety: A systematic review and meta-analysis. *Health Science Reports, 8*(8), e71176.

Kong, X., Song, N., Chen, L., & Li, Y. (2024). Non-pharmacological interventions for reducing dental anxiety in pediatric dentistry: A network meta-analysis. *BMC Oral Health, 24*(1), 1151.

Maenner, M. J., Warren, Z., Williams, A. R., et al. (2023). Prevalence and characteristics of autism spectrum disorder among children aged 8 years—Autism and Developmental Disabilities Monitoring Network, 11 sites, United States, 2020. *MMWR Surveillance Summaries, 72*(2), 1–14. https://doi.org/10.15585/mmwr.ss7202a1

Mokhtar, I. W., Suhaimi, A. S. M., Ahmad, M. S., Baharuddin, I. H., & Andytan, N. I. I. (2019). The papoose board: Parents' perceptions and attitudes of its usage in their child's dental treatment. *Journal of Dentistry Indonesia, 26*(3), 133–139. https://doi.org/10.14693/jdi.v26i3.1038

Narula, V., Goswami, M., Juneja, M., & Kumar, G. (2024). Comparative evaluation of oral health status and treatment needs of children with autism spectrum disorder: A cross-sectional study. *Cureus, 16*(4), e58663. https://doi.org/10.7759/cureus.58663

Trusculescu, L.-M., Pitic, D. E., Sălcudean, A., Popovici, R. A., Forna, N., Badoiu, S. C., Enache, A., Enasoni, S., Kiș, A., & Cosoroabă, R. M. (2025). Virtual reality as a non-pharmacological aid for reducing anxiety in pediatric dental procedures. *Children, 12*(7), 930.

Zeidan, J., Fombonne, E., Scorah, J., et al. (2022). Global prevalence of autism: A systematic review update. *Autism Research, 15*(5), 778–790. https://doi.org/10.1002/aur.2696