**JURNAL LOCUS: Penelitian & Pengabdian**
Volume 5 No. 11 November 2026, pp 10559-10578
E-ISSN 2829-7334
DOI: 10.58344/locus.v5i11.6514

# Diagnostic Accuracy of Photon-Counting Detector CT Coronary Angiography for Coronary In-Stent Restenosis Compared with Invasive Coronary Angiography: A Systematic Review

**Muhamad Haniv Al Rasyid[1*], Abdulaziez Mufakhhir[2], Yossan Harden Tambun[3], Michael Namonang Sitompul[4]**
Dr. Soedibyo Sardadi Naval Hospital, Indonesia[1]
Parung Panjang Community Health Center, Indonesia[2]
Dabo Singkep Naval Base Medical Clinic, Indonesia[3]
Banten Naval Base Medical Clinic, Indonesia[4]
Email : muhamad.haniv@gmail.com[1*], aziezmufakhhir@gmail.com[2], yossantarigan95@gmail.com[3], michaelnamonangs@gmail.com[4]

**Keywords:**
Photon-Counting Detector CT; Coronary CT Angiography; In-Stent Restenosis; Diagnostic Accuracy; Systematic Review.

This is an open access article under the CC BY-SA license.

Copyright © 2026 by Author. Published by Riviera Publishing

***ABSTRACT***

Coronary computed tomography angiography (CCTA) following coronary stent implantation is limited by metal-related artifacts, whereas photon-counting detector computed tomography (PCD-CT) offers improved spatial resolution. This systematic review evaluated the diagnostic accuracy of PCD-CT angiography for detecting in-stent restenosis (ISR) of ≥50% luminal diameter stenosis using invasive coronary angiography (ICA) as the reference standard and summarized in vivo evidence regarding coronary stent visualization. Five electronic databases were searched from inception. Two reviewers independently screened studies, extracted relevant data, and assessed the risk of bias using the Quality Assessment of Diagnostic Accuracy Studies-2 (QUADAS-2) tool. Findings were synthesized without meta-analysis in accordance with the Synthesis Without Meta-analysis (SWiM) reporting guideline, and the certainty of evidence was evaluated using the Grading of Recommendations Assessment, Development and Evaluation (GRADE) approach. Twelve studies involving 511 patients were included, comprising eight diagnostic accuracy studies and four stent visualization studies. Five diagnostic accuracy studies provided complete 2 × 2 contingency table data for 560 stents or lesions. Sensitivity ranged from 75.0% to 100.0% (median: 96.3%), specificity from 83.0% to 98.7% (median: 90.4%), and negative predictive value from 91.7% to 100.0%. Positive predictive value was below 63% in four studies. The proportion of nonevaluable stents or lesions ranged from 0.9% to 6.8%. Ultra-high-resolution reconstruction improved specificity in within-study comparisons; however, seven of the eight diagnostic accuracy studies were assessed as having a high risk of bias, primarily due to selective verification. PCD-CT coronary angiography may be useful for ruling out clinically significant coronary in-stent restenosis in selected clinical settings. However, false-positive findings and low to very low certainty of evidence limit definitive conclusions regarding its clinical utility. Further prospective diagnostic accuracy studies incorporating complete verification with invasive coronary angiography are warranted.

## INTRODUCTION

Coronary in-stent restenosis (ISR) remains an important indication for repeat diagnostic evaluation following percutaneous coronary intervention (PCI). Contemporary drug-eluting stents have reduced, but not eliminated, the occurrence of restenosis (Giacoppo et al., 2024). Giustino et al. (2022) highlighted the persistence of restenosis following coronary stent implantation, while registry data from the United States indicated that 10.6% of more than five million percutaneous coronary interventions performed between 2009 and 2017 were associated with restenosis (Moussa et al., 2020). A luminal diameter stenosis of at least 50% within the stent or its adjacent edge segments is commonly used as an angiographic criterion for ISR, although its clinical significance depends on symptoms, lesion characteristics, and the overall clinical context (Alfonso et al., 2014; Giustino et al., 2022).

Evaluating recurrent symptoms following coronary stent implantation remains challenging. Coronary computed tomography angiography (CCTA) is widely used in selected patients with suspected chronic coronary syndrome; however, conventional energy-integrating detector computed tomography (EID-CT) has limited diagnostic reliability within metallic coronary stents because blooming and beam-hardening artifacts may obscure the stent lumen (Knuuti et al., 2020; Vrints et al., 2024). Previous meta-analyses reported sensitivity and specificity estimates of approximately 90% among evaluable stents, although the presence of nonevaluable segments reduced the overall clinical utility of CCTA (Sun & Almutairi, 2010; Vanhoenacker et al., 2008). A more recent synthesis of studies using 64-detector-row or newer CT systems reported approximately 90% sensitivity and 89% specificity, with 92% of coronary stents considered fully interpretable (Dahdal et al., 2025).

These limitations are clinically relevant because patients with previously implanted coronary stents may require invasive coronary angiography (ICA), which provides detailed anatomical assessment but is associated with procedure-related risks (Tavakol et al., 2012). The diagnostic challenge involves not only detecting significant luminal narrowing but also differentiating true restenosis from artifact-induced stenosis, particularly when the degree of narrowing approaches the 50% diagnostic threshold. Existing coronary CT reporting guidelines recommend the separate assessment of stented coronary segments and nonevaluable segments (Cury et al., 2022), emphasizing the importance of evaluating both diagnostic accuracy and the proportion of stents that cannot be reliably interpreted.

Photon-counting detector computed tomography (PCD-CT) offers a potential solution through smaller effective detector elements and energy-resolved photon detection, which may overcome some limitations of conventional energy-integrating detector systems (Willemink et al., 2018; Flohr et al., 2020). Early clinical investigations demonstrated substantial improvements in spatial resolution (Rajendran et al., 2022), while studies involving native coronary artery disease reported reduced blooming artifacts and decreased overestimation of certain coronary stenoses (Halfmann et al., 2024; Vecsey-Nagy et al., 2024). Initial in vivo investigations of coronary stents similarly demonstrated improved visualization of stent struts and luminal structures. Nevertheless, improved image quality alone does not establish diagnostic accuracy unless the findings are validated against an appropriate invasive reference standard (Boccalini et al., 2022).

Existing evidence also varies in scope and methodological approach. Reviews addressing

technological advances and image quality have examined coronary stent imaging alongside other cardiovascular applications of PCD-CT (van der Bie et al., 2025; Rønning et al., 2025), whereas a preliminary synthesis specifically addressing coronary ISR was published as a research letter (Kurugalage et al., 2026b). However, these contributions have not fully clarified how diagnostic accuracy estimates are influenced by reference-standard verification procedures, the handling of nonevaluable stents, image reconstruction protocols, and differences in the units of analysis. Importantly, improvements in image quality without confirmation by ICA cannot be considered equivalent to established sensitivity and specificity estimates for detecting clinically significant ISR.

These unresolved methodological and clinical considerations highlight the research gap and urgency of the present systematic review. Apparent improvements in diagnostic performance may result from enhanced spatial resolution, differences in patient selection, or methodological decisions regarding whether indeterminate images are excluded from analysis or classified as positive findings. Accordingly, this review distinguished diagnostic accuracy studies incorporating an invasive reference standard from studies evaluating stent visualization alone. It also examined methodological risk of bias alongside diagnostic performance and image evaluability. The novelty of this review lies in its structured comparison of diagnostic accuracy and visualization evidence, with particular emphasis on methodological quality and certainty of evidence, rather than claiming to be the first investigation of PCD-CT or coronary ISR.

The primary objective of this systematic review was to evaluate the reported diagnostic accuracy of PCD-CT coronary angiography for detecting coronary ISR, defined as luminal diameter stenosis of at least 50%, using ICA as the reference standard. The secondary objectives were to assess the frequency of nonevaluable stents, examine differences associated with ultra-high-resolution (UHR) reconstruction and stent diameter, summarize in vivo evidence regarding coronary stent visualization, and evaluate the risk of bias and certainty of the available evidence. By integrating these findings through a structured synthesis without meta-analysis, the review sought to clarify the current evidence supporting diagnostic decision-making and identify priorities for future prospective diagnostic accuracy studies.

## METHOD

This systematic review followed a predefined protocol and was reported in accordance with PRISMA 2020 and the Synthesis Without Meta-analysis (SWiM) reporting guideline. STARD 2015 was used to guide the extraction of diagnostic study characteristics (Page et al., 2021; Campbell et al., 2020; Bossuyt et al., 2015). Eligible studies included adults with coronary stents who underwent in vivo photon-counting detector CT coronary angiography. Studies evaluating the detection of ≥50% in-stent restenosis against invasive coronary angiography were classified as diagnostic accuracy studies (Group A), whereas studies assessing in vivo stent visualization without an invasive reference standard were classified as visualization studies (Group B). Outcomes were extracted at the patient, vessel, stent, or lesion level, as reported. CT-derived fractional flow reserve outcomes were analyzed separately. Phantom, ex vivo, cadaveric, animal, noncoronary, duplicate-population, review, and nonoriginal research studies were excluded.

PubMed/MEDLINE, Embase, Cochrane CENTRAL, Scopus, and Web of Science were searched from database inception using terms related to photon-counting CT, coronary arteries, stents, and restenosis, without applying diagnostic accuracy filters. Database-specific search

strategies incorporated controlled vocabulary and free-text terms, as appropriate, and were provided in the supplementary materials. Trial registries, reference lists, and gray literature were not searched separately. Two reviewers independently screened deduplicated records and assessed potentially eligible full-text articles, resolving disagreements through discussion. Data were extracted using a standardized form covering study characteristics, patient populations, imaging protocols, reference standards, intervals between examinations, units of analysis, restenosis prevalence, diagnostic accuracy, stent evaluability, image quality, and radiation dose. Two-by-two contingency tables were reconstructed only when the calculated results were consistent with published diagnostic accuracy estimates. When confidence intervals were unavailable for reconstructed data, 95% Wilson score confidence intervals were calculated.

The primary outcome was diagnostic accuracy for detecting ≥50% in-stent restenosis at the stent or lesion level. Secondary outcomes included patient-level diagnostic accuracy, stent evaluability, reconstruction-related differences, stent diameter effects, visualization quality, and radiation dose. Two reviewers independently assessed the risk of bias in diagnostic accuracy studies using QUADAS-2. Visualization studies were assessed using applicable domains without evaluating the reference-standard domain (Whiting et al., 2011). Studies were not excluded solely because of their risk-of-bias ratings. A bivariate meta-analysis was not conducted because only five studies provided complete stent- or lesion-level two-by-two data, with methodological differences in reference-standard interpretation, units of analysis, and management of indeterminate findings. Instead, diagnostic accuracy estimates, confidence intervals, medians, ranges, and within-study comparisons were summarized descriptively in accordance with SWiM. The certainty of evidence was assessed using the GRADE approach for diagnostic test accuracy, considering risk of bias, inconsistency, indirectness, imprecision, and publication bias (Guyatt et al., 2008; Schünemann et al., 2020).

## RESULTS AND DISCUSSION

### Study Selection

The five database searches identified 2,520 records: 374 from PubMed/MEDLINE, 621 from Embase, 189 from Cochrane CENTRAL, 782 from Scopus and 554 from Web of Science. After removal of 902 duplicates, 1,618 records were screened on title and abstract and 1,455 were excluded. Of 163 reports sought for retrieval, seven could not be retrieved and 156 were assessed in full text (Figure 1). Of these, 144 were excluded because they did not use photon-counting detector CT (41), did not assess coronary stents (33), were reviews, editorials or commentaries (25), contained no original patient data (20), described an overlapping study population (15) or gave insufficient stent-specific data (10). Twelve studies, each published as a single report, were included.

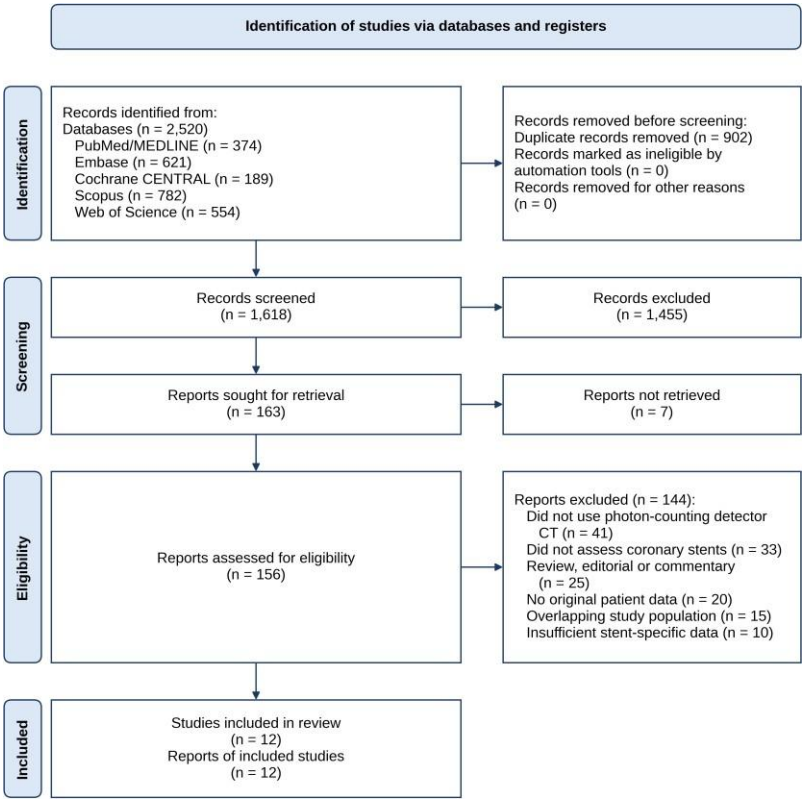


**Figure 1.** PRISMA 2020 Flow Diagram of Record Identification, Screening, Full-Text Eligibility Assessment and Inclusion

*Source: Authors' PRISMA selection data reported in the Results section (diagram follows PRISMA 2020).*

*Note: records were identified through five bibliographic databases; the number excluded at each stage and the reasons for full-text exclusion are shown to the right of that stage.*

## Characteristics of Included Studies

The studies were published between 2022 and 2026 and included 511 patients (Table 1). The eight accuracy studies contributed 383 patients with a reference standard and the four visualisation studies 128. Three accuracy studies came from Europe, two from the USA, two from China and one from centres in the USA and Hungary; two were prospective. Only one cohort exceeded 100 patients. Five used a dual-source system, named as NAEOTOM Alpha in four. Clinical indications ranged from suspected restenosis in chronic coronary syndrome to work-up before transcatheter aortic valve implantation and inflammation-associated coronary disease. Mean or median ages were around 70 years in most cohorts, but 83 years in the valve-implantation cohort and 50.4 years in the inflammatory cohort. Stent calibre was reported in two studies: the median lesion diameter was 3.00 mm in the largest cohort, and 32.1% of stents were below 3 mm in the two-centre study (Shin et al., 2025; Szilveszter et al., 2026).

**Table 1.** Characteristics of the Twelve Included Studies, by Strand

| Study | Stran d | Country; design; period | Population | Scanner; mode | Reference standard; threshold | Patients; units analysed |
|---|---|---|---|---|---|---|
| Shin et al. (2025) | A | USA; Retrospective, single centre, consecutive; 2023-2024 | Prior coronary stenting, clinically indicated CCTA followed by ICA within 90 days | Dual-source PCD-CT (NAEOTOM Alpha); Standard or UHR (0.4 or 0.2 mm) | QCA, blinded; DS 50% or more | 171; 283 stented lesions (280 determinate) |
| Szilveszter et al. (2026) | A | USA and Hungary; Retrospective, two centres, consecutive; 2023-2025 | Coronary stents, clinically indicated CCTA in chronic coronary syndrome, ICA within 8 weeks | Dual-source PCD-CT (NAEOTOM Alpha); UHR 0.2 mm against 0.4 mm standard-resolution reconstruction | ICA with QCA; DS 50% or more (obstructive); below 50% (non-obstructive) | 50; 106 stents |
| Lacaita et al. (2026) | A | Austria; Retrospective, single centre, consecutive; NR | Coronary stents referred to CCTA; ICA available in a subset | PCCT (model NR); EID-CT control group; NR | ICA; ISR 50% or more | 21; 61 stents with ICA (DERIVED) of 176 imaged in 70 patients |
| Aramouni et al. (2026) | A | USA; Retrospective, single centre, consecutive; 2025-2026 | Prior coronary stenting, clinically indicated PCD-CT followed by ICA | PCD-CT (model NR); NR | ICA; DS above 50% | 52; 69 stents |
| Xu et al. (2025) | A | China; Prospective; number of centres NR; 2022-2024 | Inflammation-associated coronary artery disease; ICA available in 40 of 63 patients | Spectral PCD-CT (model NR); Sequential, 0.4 mm; 55 keV VMI against T3D | ICA; ISR 50% or more | 40; 75 stents |
| Hagar et al. (2024) | A | Germany; Prospective, single centre, consecutive; 2022-2023 | TAVI candidates with prior coronary stents, ICA within 8 weeks | Dual-source PCD-CT (NAEOTOM Alpha); UHR, 0.2 mm, Bv60, QIR 3 | ICA, blinded adjudication; DS 50% or more | 18; 44 stents |
| Qin et al. (2024) | A | China; Single centre; enrolment design NR; 2023 | Coronary stents after angioplasty; ICA in 12 of 69 patients | Dual-source PCD-CT; UHR 0.2 mm (Bv72) against standard resolution 0.6 mm (Bv48) | ICA; NR | 12; 25 stents with ICA |
| Ayx et al. (2026) | A | Germany; Retrospective; centres NR; 2021-2024 | Coronary stents, clinically indicated cardiac PCCT; ICA in 3 of 19 patients | Dual-source PCD-CT (NAEOTOM Alpha); On-site CT-FFR distal to the stent | ICA (3 patients); no ICA assumed negative; Post-stent CT-FFR below 0.76 | 19; 19 stented vessels |

| Study | Stran d | Country; design; period | Population | Scanner; mode | Reference standard; threshold | Patients; units analysed |
|---|---|---|---|---|---|---|
| Boccalini et al. (2022) | B | France; Prospective, single centre, intraindividual; 2021 | Consecutive patients with coronary stents, two scans within 3 days | Spectral PCCT prototype (Philips) against dual-layer EID-CT; 0.25 mm, 1024 matrix, Sharp and Detailed 2 kernels | None (image quality) | 8; 16 stents (5 not evaluable on SPCCT) |
| Adolf et al. (2026) | B | Germany; Consecutive enrolment, protocol comparison; 2021-2023 | CCTA for suspected ISR or progression of coronary artery disease | First-generation dual-source PCD-CT; Standard (144 x 0.4 mm) against UHR (120 x 0.2 mm); Bv48 and Bv56 | None (image quality) | 25; NR |
| Araki et al. (2025) | B | Japan; Retrospective, single centre, propensity-matched comparison; 2023-2024 | CCTA for coronary stent evaluation | Dual-source PCD-CT (NAEOTOM Alpha) against dual-source EID-CT (Somatom Force); UHR at low tube potential against EID at low tube potential | None (image quality) | 54; 88 stents (45 PCD-CT, 43 EID-CT) |
| Gao et al. (2025) | B | China; Retrospective, single centre, intraindividual reconstruction comparison; 2024 | Isolated coronary stents after PCI imaged on PCCT | Dual-source PCD-CT (NAEOTOM Alpha); UHR 0.2 mm (Bv60, Bv72) against simulated EID-CT (0.8 mm, Bv48) | None for stent quality; ISR read on CT | 41; 51 stents |

*Source: Authors' synthesis of the 12 included studies cited in Table 1.*

*Note. Strand A, accuracy against invasive coronary angiography; strand B, in vivo stent visualisation without a reference standard. Patients are those analysed for the review outcome; where accuracy rested on a subset with angiography, the subset is given. CCTA, coronary CT angiography; DS, diameter stenosis; EID, energy-integrating detector; FFR, fractional flow reserve; ICA, invasive coronary angiography; ISR, in-stent restenosis; PCD-CT or PCCT, photon-counting detector CT; QCA, quantitative coronary angiography; TAVI, transcatheter aortic valve implantation; T3D, polychromatic images; UHR, ultra-high resolution; VMI, virtual monoenergetic images; NR, not*

*reported.*

The reference standard was invasive angiography in every accuracy study, read quantitatively in two and visually or by unstated methods in the others. Seven studies analysed stents or lesions, three of them only in the patients who had angiography, and one used CT-derived fractional flow reserve at the patient level.

**Risk of Bias**

Seven of the eight accuracy studies were at high overall risk of bias and one, in which angiography was part of the routine work-up for valve implantation, was at low risk (Tables 2 and 3). The patient-selection and flow domains drove most high ratings. Selective verification was the main problem. Several cohorts included only patients who went on to angiography after CT, so verification depended on the CT result, and in four studies only part of the imaged patients or stents had angiography. One functional study classified patients without angiography as negative. Applicability concerns arose from the elderly valve-implantation population in one study and the younger inflammatory-disease population in another. Among the visualisation studies, three were at high risk, mostly from the selection of patients or the exclusion of stents with poor image quality.

**Table 2.** Risk of Bias and Applicability Concerns of the Included Studies (QUADAS-2)

| Study | Tool | Patient selection | Index test | Reference standard | Flow and timing | Overall | Applicability: selection, index, reference |
|---|---|---|---|---|---|---|---|
| Shin et al. (2025) | QUADAS-2 | High | Low | Low | Low | High | Unclear, Low, Low |
| Szilveszter et al. (2026) | QUADAS-2 | High | Low | Low | Low | High | Low, Low, Low |
| Lacaita et al. (2026) | QUADAS-2 | Unclear | Unclear | Unclear | High | High | Unclear, Low, Low |
| Aramouni et al. (2026) | QUADAS-2 | High | Unclear | Unclear | Unclear | High | Unclear, Low, Low |
| Xu et al. (2025) | QUADAS-2 | Unclear | Unclear | Unclear | High | High | High, Unclear, Low |
| Hagar et al. (2024) | QUADAS-2 | Low | Low | Low | Low | Low | High, Low, Low |
| Qin et al. (2024) | QUADAS-2 | Unclear | Unclear | Unclear | High | High | Unclear, Low, Unclear |
| Ayx et al. (2026) | QUADAS-2 | High | Low | High | High | High | Unclear, High, Low |
| Boccalini et al. (2022) | QUADAS-2, adapted | Low | Low | NA | High | High | NA, NA, NA |
| Adolf et al. (2026) | QUADAS-2, adapted | Low | Unclear | NA | Unclear | Unclear | NA, NA, NA |
| Araki et al. (2025) | QUADAS-2, adapted | High | Unclear | NA | Low | High | NA, NA, NA |
| Gao et al. (2025) | QUADAS-2, adapted | High | Unclear | NA | Low | High | NA, NA, NA |

*Source: Authors' QUADAS-2 risk-of-bias assessments reported in this review.*

*Note. Overall risk is high when any domain is at high risk, unclear when none is high and at least one is unclear, and low otherwise. The adapted tool applies three QUADAS-2 domains to the image-quality comparison of the visualisation studies, which have no reference standard. NA, not applicable. The basis for each judgement is given in the supplementary data extraction file.*

The distribution of judgements across domains is summarised in Table 3.

**Table 3.** Risk-of-Bias Summary: Number of Studies Judged at Low, Unclear or High Risk in Each QUADAS-2 Domain

| Domain | Low | Unclear | High | Not applicable |
|---|---|---|---|---|
| Accuracy studies, QUADAS-2 (n = 8) | | | | |
| Patient selection | 1 | 3 | 4 | – |
| Index test | 4 | 4 | 0 | – |
| Reference standard | 3 | 4 | 1 | – |
| Flow and timing | 3 | 1 | 4 | – |
| Overall | 1 | 0 | 7 | – |
| Visualisation studies, adapted QUADAS-2 (n = 4) | | | | |
| Patient selection | 2 | 0 | 2 | – |
| Index test | 1 | 3 | 0 | – |
| Reference standard | – | – | – | 4 |
| Flow and timing | 2 | 1 | 1 | – |
| Overall | 0 | 1 | 3 | – |

*Source: Authors' summary of QUADAS-2 risk-of-bias assessments.*

*Note. Values are study counts; the reference-standard domain does not apply to visualisation studies.*

**Accuracy for In-Stent Restenosis**

Five studies gave two-by-two data for 560 stents or lesions, 97 of which had restenosis of 50% or more on angiography (Table 4). Sensitivity ranged from 75.0% to 100.0%, with a median of 96.3%, and specificity from 83.0% to 98.7%, with a median of 90.4% (Figure 2). Negative predictive value was 91.7% to 100.0% in all five studies, while positive predictive value was between 56.3% and 62.5% in four of them and 96.3% only in the two-centre study that read 0.2 mm ultra-high-resolution images. In the largest cohort, with 280 determinate These estimates combine lesion-level and stent-level units; their numerical ranges should not be interpreted as directly exchangeable or independent because some patients contributed multiple stents.

lesions, 23 false-positive readings were set against 32 true positives, and most false positives had been graded as 50% to 69% stenosis (Shin et al., 2025).

**Table 4.** Accuracy of Photon-Counting CT for In-Stent Restenosis Against Invasive Coronary Angiography

| Study | Unit; restenosis / units | TP / FP / FN / TN | Sensitivity, % (95% CI) | Specificity, % (95% CI) | PPV, % | NPV, % | Accuracy, % | Non-evaluable; comparison |
|---|---|---|---|---|---|---|---|---|
| Shin et al. (2025) | Lesion; 40 / 280 | 32 / 23 / 8 / 217 | 80.0 (65.2-89.5) | 90.4 (86.0-93.5) | 58.2 | 96.4 | 88.9 | 3/283 (1.1%) indeterminate, excluded from accuracy; None Evaluable 99.1% (0.2 mm) against 91.5% (0.4 mm); non-evaluable read as obstructive; 0.4 mm reconstruction: |
| Szilveszter et al. (2026) | Stent; 27 / 106 | 26 / 1 / 1 / 78 | 96.3 (81.7-99.3) | 98.7 (93.2-99.8) | 96.3 | 98.7 | 98.1 | |

| Study | Unit; restenosis / units | TP / FP / FN / TN | Sensitivity, % (95% CI) | Specificity, % (95% CI) | PPV, % | NPV, % | Accuracy, % | Non-evaluable; comparison |
|---|---|---|---|---|---|---|---|---|
| Lacaita et al. (2026) | Stent; 9 / 61 | 9 / 7 / 0 / 45 | 100 (70.08-100) | 86.54 (74.73-93.32) | 56.25 | 100 | 88.52 | sensitivity 92.6%, specificity 82.3%, PPV 64.1%, accuracy 84.9% 1.1% non-diagnostic on PCCT against 46.8% on EID-CT; EID-CT control group, 71 patients and 126 stents: image quality only |
| Aramouni et al. (2026) | Stent; 16 / 69 | 12 / 9 / 4 / 44 | 75.0 | 83.0 | 57.1 | 91.7 | 81.2 (derived) | NR; None |
| Xu et al. (2025) | Stent; NR / 75 | NR | NR | NR | NR | NR | 97.3 | NR; T3D polychromatic images: accuracy 96.0% (reader 1) and 94.7% (reader 2); 55 keV: 97.3% and 96.0% |
| Hagar et al. (2024) | Stent; 5 / 44 | 5 / 3 / 0 / 36 | 100 (47.8-100) | 92.3 (79.1-98.4) | 62.5 | 100 | 93.2 | 3/44 non-diagnostic for both readers, counted as positive; Reader 2: specificity 87.2%, accuracy 88.6% |
| Qin et al. (2024) | Stent; NR / 25 | NR | NR | NR | NR | NR | 88.0 | NR; Standard resolution: accuracy 78.3% (56.3-92.5) |
| Ayx et al. (2026) | Patient; 2 / 19 | 2 / 4 / 0 / 13 | 100 | 76.5 | 33.3 | 100 | 78.9 | NR; Visual CTA reading identified no ISR in any patient |

*Source: Authors' extraction of the diagnostic studies listed in Table 4.*

*Note. Values as printed; intervals are those reported by each study. Two-by-two tables are as printed or derived from printed values, and each derived table reproduces every printed metric. Szilveszter et al. (2026) refers to 0.2 mm ultra-high-resolution images and Hagar et al. (2024) to reader 1. Xu et al. (2025) gives accuracy for 55 keV images (reader 1). Ayx et al. (2026) is a patient-level analysis of CT-derived fractional flow reserve in which patients without angiography were counted as negative. TP, FP, FN and TN, true and false positives and negatives; PPV and NPV, positive and negative predictive values; CI, confidence interval; NR, not reported.*

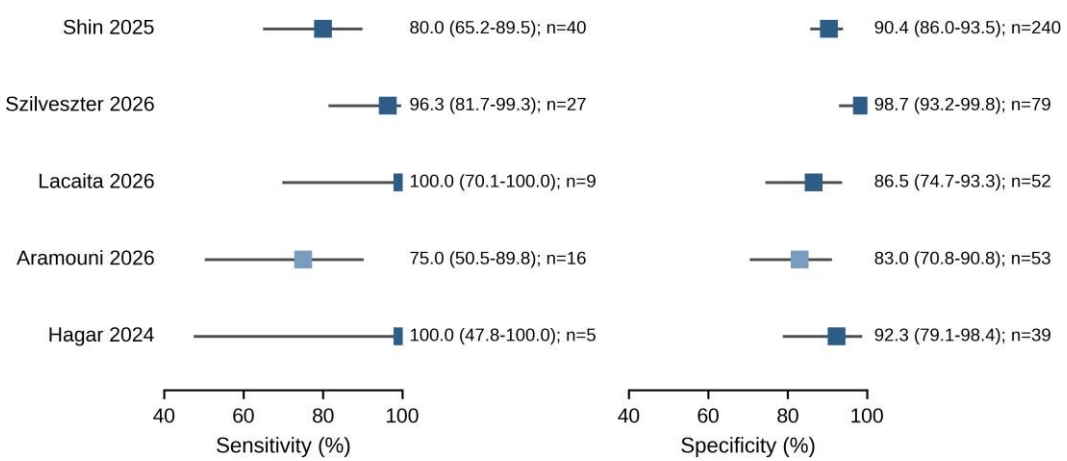


**Figure 2.** Sensitivity and Specificity of Photon-Counting CT for In-Stent Restenosis of 50% or More in the Five Studies with Complete Two-by-Two Data

*Source: Authors' synthesis of Shin et al. (2025), Szilveszter et al. (2026), Lacaita et al. (2026), Aramouni et al. (2026), and Hagar et al. (2024).*

*Note: 95% confidence intervals are shown and no summary estimate is computed. Intervals are those printed by each study; for Aramouni 2026, which printed none, Wilson intervals were computed from the derived two-by-two table. The number of restenotic and non-restenotic units is shown beside each estimate.*

The remaining studies reported accuracy without a full table. A prospective study of inflammation-associated disease reported accuracy of 97.3% and 96.0% for two readers on 55 keV monoenergetic images (Xu et al., 2025). A study of 25 stents with angiography reported accuracy of 88.0% with ultra-high-resolution images (Qin et al., 2024). At the patient level, sensitivity ranged from 77.1% to 100% in the three studies that reported it.

**Non-Evaluable Stents and Reconstruction**

Non-evaluable or indeterminate stents made up 1.1% of lesions in the largest cohort, 0.9% of stents with 0.2 mm reconstruction in the two-centre study, 1.1% in the Austrian cohort and 6.8% in the valve-implantation cohort. However, the handling differed: one study excluded indeterminate lesions from accuracy, while two counted them as positive (Shin et al., 2025; Szilveszter et al., 2026; Hagar et al., 2024). In the only comparison with a separate energy-integrating group, 46.8% of stents were non-diagnostic against 1.1% with photon-counting CT (Lacaita et al., 2026).

Two studies compared reconstructions of the same data. The 0.2 mm ultra-high-resolution images raised accuracy for obstructive restenosis from 84.9% to 98.1% and specificity from 82.3% to 98.7% against 0.4 mm images, and the proportion of evaluable stents from 91.5% to 99.1% (Szilveszter et al., 2026). Accuracy rose from 78.3% to 88.0% with a sharp ultra-high-resolution kernel in the second study (Qin et al., 2024). For stents below 3 mm, accuracy was 94.1% with thin-slice images against 79.4% with 0.4 mm images (Szilveszter et al., 2026), the largest cohort found no difference by diameter (Shin et al., 2025), and a third study reported a lower area under the curve in small stents that did not reach significance (Aramouni et al., 2026).

In the functional study, CT-derived fractional flow reserve distal to the stent identified both

patients with confirmed restenosis, with specificity of 76.5%, although visual reading of the same images had called no stent restenotic and only 3 of 19 patients underwent angiography (Ayx et al., 2026).

**Stent Visualisation**

All four visualisation studies favoured photon-counting CT or its ultra-high-resolution mode (Table 5). Against a propensity-matched energy-integrating group, blooming fell from 47.1% to 28.1% and good or excellent in-stent image quality rose from 53.5% to 82.2%, at a similar dose (Araki et al., 2025). In an intraindividual comparison with a spectral prototype, blooming was 53% against 71% (Boccalini et al., 2022). Similarly, within photon-counting data, ultra-high-resolution reconstruction with sharper kernels widened the visible lumen and reduced blooming and beam hardening, most clearly at lower tube voltage (Gao et al., 2025; Adolf et al., 2026).

**Table 5.** In Vivo Stent Visualisation with Photon-Counting CT in the Four Studies Without a Reference Standard

| Study | Comparison | Patients; stents | Main findings as reported | Dose |
|---|---|---|---|---|
| Boccalini et al. (2022) | Spectral PCCT prototype (Philips) against dual-layer EID-CT; 0.25 mm, 1024 matrix, Sharp and Detailed 2 kernels | 8; 16 stents (5 not evaluable on SPCCT) | Smaller external and larger internal stent diameters and less blooming on SPCCT ($P < 0.05$); blooming 53% on SPCCT-Sharp against 71% on EID-DLCT-XCD | CTDIvol 25.7 mGy (SPCCT) against median 35.7 mGy (EID) |
| Adolf et al. (2026) | First-generation dual-source PCD-CT; Standard (144 x 0.4 mm) against UHR (120 x 0.2 mm); Bv48 and Bv56 | 25; NR | UHR with Bv56 gave thinner vessel walls and fewer beam hardening artefacts than standard mode with Bv48, most clearly at lower tube voltage | NR |
| Araki et al. (2025) | Dual-source PCD-CT (NAEOTOM Alpha) against dual-source EID-CT (Somatom Force); UHR at low tube potential against EID at low tube potential | 54; 88 stents (45 PCD-CT, 43 EID-CT) | Blooming 28.1% on PCD-CT against 47.1% on EID-CT; in-stent image quality good or excellent in 82.2% against 53.5% | CTDIvol 9.3 against 10.5 mGy; DLP 107.1 against 118.2 mGy cm |
| Gao et al. (2025) | Dual-source PCD-CT (NAEOTOM Alpha); UHR 0.2 mm (Bv60, Bv72) against simulated EID-CT (0.8 mm, Bv48) | 41; 51 stents | Larger in-stent diameters and less blooming with 0.2 mm Bv72 than with simulated EID-CT ($P < 0.001$); peri-stent FAI separated stents with and without ISR (AUC 0.703) | NR |

*Source: Authors' synthesis of the visualisation studies listed in Table 5.*

*Note. Blooming is the proportion of the stent diameter taken up by artefact, as each study defined it. CTDIvol, volume CT dose index; DLP, dose-length product; EID, energy-integrating detector; FAI, fat attenuation index; NR, not reported.*

**Certainty of Evidence**

Certainty was low for specificity and very low for sensitivity, both rated down for risk of bias and inconsistency and sensitivity further for imprecision, given 97 restenotic units in total (Table 6). The low proportion of non-evaluable stents was rated moderate. The advantage of ultra-high-resolution reconstruction and the findings in small stents were rated very low, and

better visualisation than energy-integrating CT was rated low because image quality is a surrogate for accuracy. No finding reached high certainty. Although evaluability was rated as moderate-certainty evidence in Table 6, the underlying studies differed in definitions, reference populations, and whether indeterminate images were excluded or counted as positive. This difference limits comparability and warrants caution in applying the rating.

**Table 6.** Certainty of the Principal Findings (GRADE for Test Accuracy)

| Finding | Studies (units or patients) | Risk of bias | Inconsistency | Indirectness | Imprecision | Publication bias | Certainty |
|---|---|---|---|---|---|---|---|
| Sensitivity for restenosis of 50% or more (stent or lesion level): 75.0% to 100%, median 96.3% | 5 (560 units; 97 with restenosis) | Serious | Serious | Not serious | Serious | Not assessed | Very low |
| Specificity (stent or lesion level): 83.0% to 98.7%, median 90.4% | 5 (560 units; 463 without restenosis) | Serious | Serious | Not serious | Not serious | Not assessed | Low |
| Non-evaluable stents: 0.9% to 6.8% | 4 (609 stents or lesions) | Serious | Not serious | Not serious | Not serious | Not assessed | Moderate |
| Ultra-high-resolution against standard-resolution reconstruction: higher accuracy and specificity | 2 (131 stents) | Serious | Not serious | Serious | Serious | Not assessed | Very low |
| Stents below 3 mm: accuracy similar to or lower than in larger stents | 3 (273 patients) | Serious | Serious | Not serious | Serious | Not assessed | Very low |
| Visualisation against energy-integrating CT: fewer non-diagnostic stents and less blooming | 3 (203 patients) | Serious | Not serious | Serious | Not serious | Not assessed | Low |

*Source: Authors' GRADE certainty assessments reported in this review.*

*Note. Cross-sectional accuracy studies start at high certainty. Risk of bias: verification limited to patients referred for angiography or to a subset, and exclusion of non-evaluable stents. Inconsistency: per-study estimates that do not overlap. Indirectness: reconstructions of the same data standing in for energy-integrating CT, and image quality standing in for accuracy. Imprecision: few restenotic stents and wide intervals. Publication bias was not assessed without pooling. The 609 units are 283 lesions, 106 stents, 176 stents and 44 stents; the 131 stents are 106 and 25; the 273 patients are 171, 50 and 52; the 203 patients are 141, 54 and 8.*

## Principal Findings

Overall, photon-counting CT studies reported relatively high negative predictive values and low proportions of non-evaluable stents, whereas false-positive readings remained frequent in several cohorts. These findings suggest potential usefulness for excluding significant restenosis in selected patients, but they do not establish a reliable stand-alone rule-out strategy for all patients. Seven of eight accuracy studies were at high overall risk of bias, and certainty for diagnostic sensitivity or specificity was rated low or very low.

For clinical decision-making, a negative examination may be informative when image quality is adequate and the pre-test likelihood is appropriate. However, the reported negative predictive values depend on the prevalence of restenosis and on which patients underwent invasive verification. Positive findings, especially moderate narrowing, may require confirmation with other evidence. The evidence should therefore inform cautious triage rather than immediate replacement of invasive angiography.

**Comparison with Previous Evidence**

Meta-analyses of energy-integrating CT reported pooled sensitivity and specificity of about 90% for assessable stents, with roughly one stent in ten not assessable and lower accuracy when those stents were counted (Sun & Almutairi, 2010; Vanhoenacker et al., 2008). The most recent synthesis of 64-slice or newer systems found sensitivity of 90%, specificity of 89% and 92% of stents fully interpretable (Dahdal et al., 2025). The photon-counting estimates here overlap those values. The clearest difference lies in evaluability. Non-evaluable stents fell to a few per cent, and in the only between-group comparison the difference was 1.1% against 46.8% (Lacaita et al., 2026). However, that contrast should be read with care, because the energy-integrating group in that study was historical and not matched for stent size or indication.

For native coronary stenosis, reviews published in 2026 found high sensitivity, better performance in heavily calcified disease than with conventional CT, and fewer downstream invasive angiograms (Wang et al., 2026; Alzahrani et al., 2026; Kurugalage et al., 2026a). The present findings in stents show the same direction for specificity in within-study comparisons of reconstruction, but not a consistent gain across studies. A preliminary meta-analysis of restenosis appeared as a research letter (Kurugalage et al., 2026b); the present review adds a structured appraisal of verification and of non-evaluable stents, which explains much of the spread in specificity and positive predictive value, and it separates accuracy from visualisation evidence. Narrative reviews had anticipated the role of thin slices and sharp kernels (van der Bie et al., 2025), and a review of image quality and dose reached similar conclusions on visualisation (Rønning et al., 2025).

Functional assessment is the other route to fewer false positives. In stented patients scanned on energy-integrating systems, adding stress perfusion improved both the proportion of diagnostic examinations and accuracy (Andreini et al., 2020), although pooled per-stent performance did not differ between CT angiography alone and combined with perfusion (Dahdal et al., 2025). The single photon-counting study of CT-derived fractional flow reserve is too small and too incompletely verified to judge (Ayx et al., 2026). Whether photon-counting anatomy alone matches combined anatomical and functional testing on older scanners remains untested.

A further comparison concerns the reference itself. Invasive angiography is a projection technique, and visual grading of in-stent narrowing is known to vary between readers. Quantitative angiography, used in two studies, reduces that variation but still measures a two-dimensional silhouette. Intravascular imaging would be a stricter reference, but no included accuracy study used it. Some apparent false positives may therefore be lesions that angiography underestimates.

**Possible Explanations**

Spatial resolution is the most direct explanation. Blooming arises from partial-volume averaging of dense struts, and the smaller detector elements of photon-counting systems, combined with 0.2 mm slices and sharp kernels, reduce the apparent strut thickness and widen the visible lumen (Willemink et al., 2018; Flohr et al., 2020). The within-study comparisons are the strongest evidence for this, because the same patients and stents were read at two resolutions and specificity rose sharply with the thinner slices (Szilveszter et al., 2026). Phantom work with ultra-high-resolution energy-integrating detectors shows a similar effect

(Nishii et al., 2022), which suggests that resolution rather than photon counting itself carries much of the gain.

The low positive predictive values have at least two further explanations. Prevalence of restenosis in these cohorts was between 11% and 26%, and predictive values move with prevalence even when sensitivity and specificity do not (Leeflang et al., 2013). In addition, most false positives in the largest cohort were graded 50% to 69% on CT, so the threshold sits where neointimal tissue and residual blooming are hardest to separate, and visual reading against quantitative angiography may overcall borderline lesions (Shin et al., 2025). Native-vessel work shows that photon-counting CT reduces but does not remove stenosis overestimation against quantitative angiography (Halfmann et al., 2024; Vecsey-Nagy et al., 2024). Borderline lesions remain the weak point.

Study design probably inflates some estimates. When only patients referred to angiography after CT are verified, the cohort is enriched for positive CT results, which raises apparent sensitivity and lowers apparent specificity (Whiting et al., 2011; Schünemann et al., 2020). Excluding indeterminate stents improves accuracy, whereas counting them as positive lowers specificity, and the included studies did both. The single study at low risk of bias, in which every patient had angiography for reasons unrelated to CT, found sensitivity of 100% with specificity of 92.3%, but it had only five restenotic stents (Hagar et al., 2024).

Reconstruction choices add a further source of variation. Sharper kernels and thinner slices reduce blooming but raise image noise, so the gain in lumen visibility is partly offset by a noisier lumen, and the best kernel differed between studies (Qin et al., 2024; Gao et al., 2025). In contrast, spectral information has been tested less. Low-keV monoenergetic images improved accuracy for native stenosis but did not change accuracy for restenosis in the one study that compared them (Xu et al., 2025). Finally, motion matters. Five of 16 stents could not be evaluated on a prototype system, a reminder that spatial resolution helps only when temporal resolution keeps pace (Boccalini et al., 2022).

**Strengths and Limitations**

This review has several strengths. Five databases were searched, two reviewers screened, assessed and appraised every study independently, and every included report was assessed in full text. Each extracted number was checked against a verbatim quotation from its source, and derived two-by-two tables were kept only when they reproduced all printed values. Accuracy and visualisation studies were kept apart, so that image-quality evidence did not stand in for accuracy, and risk of bias was appraised with QUADAS-2 with an explicit basis for each judgement.

The limitations are substantial. Trial registers, reference lists and grey literature were not searched as separate sources, and seven potentially eligible reports could not be retrieved, so some studies may have been missed. The evidence comes from a small number of mostly single-centre cohorts using one commercial system, and most studies analysed stents without accounting for clustering within patients. Moreover, verification was incomplete or dependent on the CT result in most accuracy studies. No pooled estimate was produced, which avoids false precision but leaves overall accuracy described rather than quantified. Finally, inter-reader agreement was only substantial where it was reported, with kappa values around 0.7, so single-reader results may not generalise to less experienced readers (Shin et al., 2025; Hagar et

al., 2024).

## CONCLUSION

Across 12 in vivo studies involving 511 patients, photon-counting detector computed tomography (PCD-CT) coronary angiography demonstrated promising negative predictive values and low proportions of nonevaluable stents in the assessment of coronary in-stent restenosis (ISR). In five studies providing complete stent- or lesion-level 2 × 2 contingency table data, sensitivity ranged from 75.0% to 100.0%, while specificity ranged from 83.0% to 98.7%. Ultra-high-resolution reconstruction improved diagnostic performance in within-study comparisons; however, false-positive findings remained a concern, and most diagnostic accuracy studies were assessed as having a high risk of bias. Therefore, these findings suggest the potential clinical utility of PCD-CT coronary angiography but do not provide sufficient evidence to support its use as a definitive replacement for invasive coronary angiography (ICA).

Future prospective, multicenter studies should employ consecutive patient recruitment and complete, independent verification using ICA. These studies should consistently report diagnostic accuracy at both the stent and patient levels, document indeterminate imaging findings, and specifically evaluate coronary stents with diameters below 3 mm. Direct comparisons between contemporary photon-counting detector CT and conventional energy-integrating detector CT systems should also examine the effects of reconstruction parameters, account for clustering of multiple stents within individual patients, and report confidence intervals for diagnostic performance estimates. Until more robust evidence becomes available, PCD-CT coronary angiography findings should be interpreted in conjunction with clinical symptoms, pretest probability, stent characteristics, and the potential need for invasive confirmation of positive or equivocal results.

## FUNDING

This research did not receive special funding from governmental, commercial, or non-profit organizations.

## CONFLICT OF INTEREST

The authors state that there is no conflict of interest in the preparation of this article.

## AUTHOR CONTRIBUTION

All authors contributed to conceptualization, search and synthesis of literature, interpretation of results, manuscript preparation, and critical review of manuscripts. All authors have read and approved the final version of the manuscript.

## GENERATIVE ARTIFICIAL INTELLIGENCE USAGE STATEMENT

The authors declare that Generative Artificial Intelligence (Generative AI) was used solely to assist with language refinement, grammatical correction, and improvement of manuscript readability. All scientific concepts, interpretations, literature synthesis, analyses, and conclusions were developed by the authors. All AI-assisted content was carefully reviewed,

verified, and revised by the authors, who take full responsibility for the accuracy, integrity, and final content of the manuscript.

## REFERENCES

Adolf, R., Ried, I., Will, A., Hendrich, E., Bressem, K., Engel, L. C., et al. (2026). Assessing beam hardening artifacts in coronary stent imaging using different CT acquisition parameters on photon-counting detector computed tomography. *Int J Cardiovasc Imaging*, *42*(3), 411–421. https://doi.org/10.1007/s10554-025-03392-z

Alfonso, F., Byrne, R. A., Rivero, F., & Kastrati, A. (2014). Current treatment of in-stent restenosis. *J Am Coll Cardiol*, *63*(24), 2659–2673. https://doi.org/10.1016/j.jacc.2014.02.545

Alzahrani, N. M., Alzahrani, A., Almutlaq, Z. M., Alghamdi, A., Almukhlifi, Y., Alotaibi, S. A., et al. (2026). Diagnostic Performance of Photon-Counting CT Angiography in Vascular Stenosis Assessment: A Systematic Review and Meta-Analysis. *Diagnostics (Basel)*, *16*(6), 881. https://doi.org/10.3390/diagnostics16060881

Andreini, D., Mushtaq, S., Pontone, G., Conte, E., Collet, C., Sonck, J., et al. (2020). CT Perfusion Versus Coronary CT Angiography in Patients With Suspected In-Stent Restenosis or CAD Progression. *JACC Cardiovasc Imaging*, *13*(3), 732–742. https://doi.org/10.1016/j.jcmg.2019.05.031

Araki, S., Nakamura, S., Okabe, S., Takafuji, M., Ichikawa, Y., Sakuma, H., et al. (2025). Low-tube-potential ultra-high-resolution coronary CTA with photon-counting detector CT for stent evaluation: a comparative feasibility study. *Jpn J Radiol*, *43*(12), 1981–1992. https://doi.org/10.1007/s11604-025-01846-x

Aramouni, K., Kharsa, C., Sarkis, P., Shah, A. R., & Ahmed, W. (2026). Diagnostic accuracy of photon-counting detector CT for detection of coronary in-stent restenosis. *Cardiovasc Revasc Med*, S1553-8389(26)00393-3. https://doi.org/10.1016/j.carrev.2026.09.009

Ayx, I., Waßmer, F., Lichti, L., Froelich, M. F., Buettner, S., Papavassiliu, T., et al. (2026). Feasibility of On-Site CT-FFR Analysis in Ruling Out In-Stent Restenosis on Cardiac PCCT. *J Cardiovasc Dev Dis*, *13*(7), 308. https://doi.org/10.3390/jcdd13070308

Boccalini, S., Si-Mohamed, S. A., Lacombe, H., Diaw, A., Varasteh, M., Rodesch, P. A., et al. (2022). First In-Human Results of Computed Tomography Angiography for Coronary Stent Assessment With a Spectral Photon Counting Computed Tomography. *Invest Radiol*, *57*(4), 212- 221. https://doi.org/10.1097/RLI.0000000000000835

Bossuyt, P. M., Reitsma, J. B., Bruns, D. E., Gatsonis, C. A., Glasziou, P. P., Irwig, L., et al. (2015). STARD 2015: an updated list of essential items for reporting diagnostic accuracy studies. *BMJ*, *351*, h5527. https://doi.org/10.1136/bmj.h5527

Campbell, M., McKenzie, J. E., Sowden, A., Katikireddi, S. V., Brennan, S. E., Ellis, S., et al. (2020). Synthesis without meta-analysis (SWiM) in systematic reviews: reporting guideline. *BMJ*, *368*, l6890. https://doi.org/10.1136/bmj.l6890

Cury, R. C., Leipsic, J., Abbara, S., Achenbach, S., Berman, D., Bittencourt, M., et al. (2022). CAD-RADS™ 2.0 - 2022 Coronary Artery Disease-Reporting and Data System: An Expert Consensus Document of the Society of Cardiovascular Computed Tomography (SCCT), the American College of Cardiology (ACC), the American College of Radiology (ACR), and the North America Society of Cardiovascular Imaging (NASCI). *J Cardiovasc Comput Tomogr*, *16*(6), 536–557. https://doi.org/10.1016/j.jcct.2022.07.002

Dahdal, J., Jukema, R. A., Remmelzwaal, S., Raijmakers, P. G., van der Harst, P., Guglielmo, M., et al. (2025). Diagnostic performance of CCTA and CTP imaging for clinically suspected in-stent restenosis: A meta-analysis. *J Cardiovasc Comput Tomogr*, *19*(2),

183–190. https://doi.org/10.1016/j.jcct.2024.10.014

Flohr, T., Petersilka, M., Henning, A., Ulzheimer, S., Ferda, J., & Schmidt, B. (2020). Photon-counting CT review. *Phys Med*, *79*, 126–136. https://doi.org/10.1016/j.ejmp.2020.10.030

Gao, Y., Yang, Y., Hu, Q., Zhao, Y., Yuan, Y., Chen, J., et al. (2025). Photon counting CT improves coronary stent imaging and fat attenuation index assessment across reconstruction modes. *Eur J Radiol Open*, *15*, 100695. https://doi.org/10.1016/j.ejro.2025.100695

Giacoppo, D., Mazzone, P. M., & Capodanno, D. (2024). Current Management of In-Stent Restenosis. *Journal of Clinical Medicine*, *13*(8), 2377. https://doi.org/10.3390/jcm13082377

Giustino, G., Colombo, A., Camaj, A., Yasumura, K., Mehran, R., Stone, G. W., et al. (2022). Coronary In-Stent Restenosis: JACC State-of-the-Art Review. *J Am Coll Cardiol*, *80*(4), 348–372. https://doi.org/10.1016/j.jacc.2022.05.017

Guyatt, G. H., Oxman, A. D., Vist, G. E., Kunz, R., Falck-Ytter, Y., Alonso-Coello, P., et al. (2008). GRADE: an emerging consensus on rating quality of evidence and strength of recommendations. *BMJ*, *336*(7650), 924–926. https://doi.org/10.1136/bmj.39489.470347.AD

Hagar, M. T., Soschynski, M., Saffar, R., Molina-Fuentes, M. F., Weiss, J., Rau, A., et al. (2024). Ultra-high-resolution photon-counting detector CT in evaluating coronary stent patency: a comparison to invasive coronary angiography. *Eur Radiol*, *34*(7), 4273–4283. https://doi.org/10.1007/s00330-023-10516-3

Halfmann, M. C., Bockius, S., Emrich, T., Hell, M., Schoepf, U. J., Laux, G. S., et al. (2024). Ultrahigh-Spatial-Resolution Photon-counting Detector CT Angiography of Coronary Artery Disease for Stenosis Assessment. *Radiology*, *310*(2), e231956. https://doi.org/10.1148/radiol.231956

Knuuti, J., Wijns, W., Saraste, A., Capodanno, D., Barbato, E., Funck-Brentano, C., et al. (2020). 2019 ESC Guidelines for the diagnosis and management of chronic coronary syndromes. *Eur Heart J*, *41*(3), 407–477. https://doi.org/10.1093/eurheartj/ehz425

Kurugalage, R., Bhatia, A., Mukherjee, A., K, G., Figtree, G. A., Bursill, C. A., et al. (2026a). Comparison of Photon-Counting and Energy-Integrating Computed Coronary Tomography Angiography for Coronary Artery Disease: A Systematic Review and Meta-Analysis. *JACC Cardiovasc Imaging*, S1936-878X(26)00318-9. https://doi.org/10.1016/j.jcmg.2026.05.021

Kurugalage, R., Bhatia, A., Khan, N., Mukherjee, A., Marathe, J. A., & Psaltis, P. J. (2026b). Diagnostic accuracy of photon-counting CT for in-stent restenosis: A preliminary meta-analysis. *J Cardiovasc Comput Tomogr*, S1934-5925(26)00409-0. https://doi.org/10.1016/j.jcct.2026.06.014

Lacaita, P. G., Bilgeri, V., Spitaler, P., Kindl, B., Dichtl, W., Lechner, I., et al. (2026). In vivo coronary stent evaluation using photon-counting computed tomography: diagnostic performance. *Eur Radiol*. https://doi.org/10.1007/s00330-026-12860-6

Leeflang, M. M., Rutjes, A. W., Reitsma, J. B., Hooft, L., & Bossuyt, P. M. (2013). Variation of a test's sensitivity and specificity with disease prevalence. *CMAJ*, *185*(11), E537–544. https://doi.org/10.1503/cmaj.121286

Moussa, I. D., Mohananey, D., Saucedo, J., Stone, G. W., Yeh, R. W., Kennedy, K. F., et al. (2020). Trends and Outcomes of Restenosis After Coronary Stent Implantation in the United States. *J Am Coll Cardiol*, *76*(13), 1521–1531. https://doi.org/10.1016/j.jacc.2020.08.002

Nishii, T., Funama, Y., Kato, S., Iwasawa, T., Yasuda, N., Ota, Y., et al. (2022). Comparison

of visibility of in-stent restenosis between conventional- and ultra-high spatial resolution computed tomography: coronary arterial phantom study. *Jpn J Radiol*, *40*(3), 279–288. https://doi.org/10.1007/s11604-021-01200-x

Page, M. J., McKenzie, J. E., Bossuyt, P. M., Boutron, I., Hoffmann, T. C., Mulrow, C. D., et al. (2021). The PRISMA 2020 statement: an updated guideline for reporting systematic reviews. *BMJ*, *372*, n71. https://doi.org/10.1136/bmj.n71

Qin, L., Zhou, S., Dong, H., Li, J., Zhang, R., Yang, C., et al. (2024). Improvement of coronary stent visualization using ultra-high-resolution photon-counting detector CT. *Eur Radiol*, *34*(10), 6568–6577. https://doi.org/10.1007/s00330-024-10760-1

Rajendran, K., Petersilka, M., Henning, A., Shanblatt, E. R., Schmidt, B., Flohr, T. G., et al. (2022). First Clinical Photon-counting Detector CT System: Technical Evaluation. *Radiology*, *303*(1), 130–138. https://doi.org/10.1148/radiol.212579

Rønning, M., Johansen, E., & Rusandu, A. (2025). Photon-counting CT versus energy-integrating detectors for cardiac imaging: a systematic review of evidence from in vivo human studies on image quality and radiation dose. *BMC Med Imaging*, *25*(1), 295. https://doi.org/10.1186/s12880-025-01825-8

Schünemann, H. J., Mustafa, R. A., Brozek, J., Steingart, K. R., Leeflang, M., Murad, M. H., et al. (2020). GRADE guidelines: 21 part 1. Study design, risk of bias, and indirectness in rating the certainty across a body of evidence for test accuracy. *J Clin Epidemiol*, *122*, 129–141. https://doi.org/10.1016/j.jclinepi.2019.12.020

Shin, D., Volleberg, R. H. J. A., Parikh, R., Yang Koo, C. C., Malik, S., Cannata, M., et al. (2025). Photon-counting detector computed tomography for the assessment of coronary stents and in-stent restenosis. *EuroIntervention*, *21*(19), e1137–e1146. https://doi.org/10.4244/EIJ-D-25-00257

Sun, Z., & Almutairi, A. M. (2010). Diagnostic accuracy of 64 multislice CT angiography in the assessment of coronary in-stent restenosis: a meta-analysis. *Eur J Radiol*, *73*(2), 266–273. https://doi.org/10.1016/j.ejrad.2008.10.025

Szilveszter, B., Hagar, M. T., Kulyassa, P., Sipos, B., Kubovje, A., Vattay, B., et al. (2026). Assessing coronary in-stent restenosis using ultrahigh-resolution photon-counting detector CT: results from a two-center study. *Eur J Radiol*, *199*, 112766. https://doi.org/10.1016/j.ejrad.2026.112766

Tavakol, M., Ashraf, S., & Brener, S. J. (2012). Risks and complications of coronary angiography: a comprehensive review. *Glob J Health Sci*, *4*(1), 65–93. https://doi.org/10.5539/gjhs.v4n1p65

van der Bie, J., Sharma, S. P., Hirsch, A., Boccalini, S., van Mieghem, N. M., Dijkshoorn, M. L., et al. (2025). Coronary Stent Imaging with Photon-counting Detector CT. *Radiol Cardiothorac Imaging*, *7*(3), e240338. https://doi.org/10.1148/ryct.240338

Vanhoenacker, P. K., Decramer, I., Bladt, O., Sarno, G., Van Hul, E., Wijns, W., et al. (2008). Multidetector computed tomography angiography for assessment of in-stent restenosis: meta-analysis of diagnostic performance. *BMC Med Imaging*, *8*, 14. https://doi.org/10.1186/1471-2342-8-14

Vecsey-Nagy, M., Tremamunno, G., Schoepf, U. J., Gnasso, C., Zsarnóczay, E., Fink, N., et al. (2024). Intraindividual Comparison of Ultrahigh-Spatial-Resolution Photon-Counting Detector CT and Energy-Integrating Detector CT for Coronary Stenosis Measurement. *Circ Cardiovasc Imaging*, *17*(10), e017112. https://doi.org/10.1161/CIRCIMAGING.124.017112

Vrints, C., Andreotti, F., Koskinas, K. C., Rossello, X., Adamo, M., Ainslie, J., et al. (2024). 2024 ESC Guidelines for the management of chronic coronary syndromes. *Eur Heart J*, *45*(36), 3415–3537. https://doi.org/10.1093/eurheartj/ehae177

Wang, R., Zhao, W., Lv, B., Lei, Q., Tian, X., Guo, Y., et al. (2026). Diagnostic accuracy of photon-counting computed tomography for detecting coronary artery stenosis: a systematic review and meta-analysis. *Heart*, heartjnl-2025-327108. https://doi.org/10.1136/heartjnl-2025-327108

Whiting, P. F., Rutjes, A. W., Westwood, M. E., Mallett, S., Deeks, J. J., Reitsma, J. B., et al. (2011). QUADAS-2: a revised tool for the quality assessment of diagnostic accuracy studies. *Ann Intern Med*, *155*(8), 529–536. https://doi.org/10.7326/0003-4819-155-8-201110180-00009

Willemink, M. J., Persson, M., Pourmorteza, A., Pelc, N. J., & Fleischmann, D. (2018). Photon-counting CT: Technical Principles and Clinical Prospects. *Radiology*, *289*(2), 293–312. https://doi.org/10.1148/radiol.2018172656

Xu, C., Sun, Y., Wang, L., Zou, L., Wang, M., Lin, L., et al. (2025). Spectral Photon-Counting Detector Coronary CTA With Reduced Radiation and Contrast Medium Dose in Inflammation-Associated Coronary Artery Disease: A Prospective Study. *AJR Am J Roentgenol*, *225*(6), e2533493. https://doi.org/10.2214/AJR.25.33493